

A case of Renal Stone ,UTI with Severe low back pain.

A patient came to me at the age of 33 years he is a truck driver complaining about Severe low back pain with burning , and cutting pain during urination and frequent desire for urination..

USG: Hepatomegaly Right sided Hydronephrosis and renal Calculus.

Homeopathy Approach

Appetite: Normal, Can't tolerate hunger

Desire: Hot food, sweet

Sleep: not good

Stool: normal

Urine: Burning, stinging frequent: desire

Prescription: profuse

Abdomen: distended, pain liver region,

Back : low back pain

Treatment:

18/08/23

Lycopodium clav 30/ 4 dose

+ Berbaris vul Ø BD/ 15 DAYS

31/08/23

Repet same medicine same dose

27/09/23

Lycopodium 200/1dose+ Berbaris vulgaris Ø TDS X 15 DAYS

No pain no burning urination

27/02/24

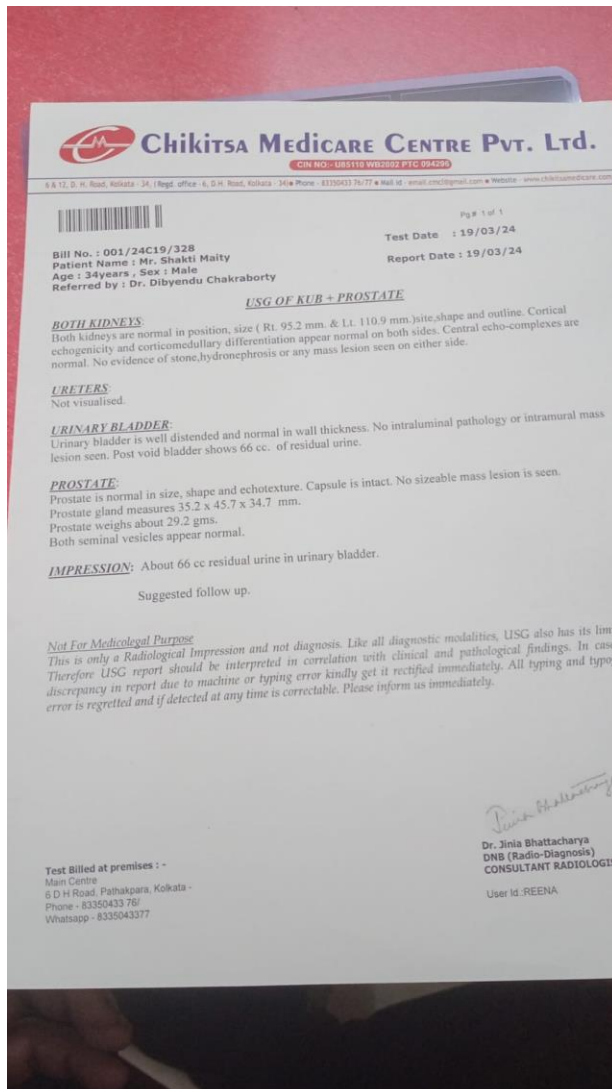
Lycopodium 1M/1 dose

PL 300 / 30 dose

No problem, better than before

19/03/24

No Stone, better than before. Renal Calculus expelled through urine.. C



ured case

Chikitsa Medicare Centre Pvt. Ltd.

CIN NO: UR5110 WB2002 PTC 094205

Head Office: 34, Regt. office, 6, D.H. Road, Kolkata - 74 • Phone: 83350433 76/77 • Mail id: sonar.com@chikitsa.com • Website: www.chikitsamedic.org



Pg # 2 of 2

Bill No. : 001/23310/199
Patient Name : Mr. Shakti Maity
Age : 33years , Sex : Male
Referred by : Dr. Dibyendu Chakraborty

Test Date : 10/10/23
Report Date : 10/10/23

URINARY BLADDER – Is normal in shape and size. Walls are smooth and regular. Lumen is clear. No obvious calculus noted in its lumen. Prevoid bladder volume is approx 799 cc. Post void scan shows about 92 cc residual urine.

PROSTATE – Is normal in size, with normal outline and normal parenchymal echotexture. Prostatic capsule is intact. It measures 30 mm x 41 mm x 37 mm. Volume = 22.4 ml.

PERITONEUM AND RETROPERITONEUM:

Ascites is not detected. Aorta and IVC are normal. Pre and para aortic lymph nodes are not enlarged.

* Both iliac fossae show no obvious abnormality sonologically.

IMPRESSION:

Present study shows:-

- 1) Right sided nephrolithiasis with mild hydronephrosis.
Calculus at right pelviureteric junction and right vesicoureteric junction with mild hydroureter.
- 2) About 92 cc residual urine in urinary bladder.
- 3) Hepatomegaly with fatty changes & fatty infiltration (Grade II).

SUGGEST

: Clinical correlation, further investigation and follow up scan if indicated.

Not For Medicolegal Purpose

This is only a Radiological Impression and not diagnosis. Like all diagnostic modalities, USG also has its limitations. Therefore USG report should be interpreted in correlation with clinical and pathological findings. In case of any discrepancy in report due to machine or typing error kindly get it rectified immediately. All typing and typographical error is regretted and if detected at any time is correctable. Please inform us immediately.

Test Billed at premises : -
Main Centre
6 D H Road, Pathakpara, Kolkata -
Phone - 83350433 76/
Whatsapp - 8335043377

Dr. Sovon Kumar Karmakar
MBBS, PGDUS, CBET
SONOLOGIST

User Id.:SHARMISTHA



NEW SANJIVAN Diagnostic & Polyclinic Centre
A Fully Computerised Diagnostic Centre (Govt. Regd. & Licensed)



ACC. NO.	: 16082023/0070	DRAWN ON	: 16-08-2023 10:54 AM
NAME	: SHAKTI MAITY	RECEIVED ON	: 17-08-2023 10:55 AM
AGE / SEX	: 33 Years / Male	REPORTED ON	: 17-08-2023 01:04 PM
REF. DOCTOR	: Dr. NAZIMUL ISLAM SARDAR	CENTER	: LAB

KIDNEYS :-

They are normal in shape, size, contour.
Cortices are of normal thickness and echogenicity. Cortico-medullary differentiation is well maintained.

Right kidney measures : 108 mm X 46 mm.
Presence of a calculus in junction of lower pole & middle pole calyx of right kidney measures : 8 mm
There is no hydronephrosis.

Left kidney measures : 106 mm x 48 mm. There is no calculus nor hydronephrosis.

URETERS :-

Pelvi-ureteric and vesico-ureteric junctions appear normal.

URINARY BLADDER :-

Bladder is normal in contour without any focal abnormalities in its wall. There is no papillary growth nor any intravesical abnormalities.

PROSTATE :-

Prostate is high normal in size and shape, Echopattern is normal without any SOL or calcification.
Prostate measuring : 45 mm x 42 mm x 35 mm.
VOL - 29.41 cc.

Right iliac fossa is normal.

No collection.

Mild probe tenderness noted.

No ascites is seen.

**IMPRESSION : HEPATOSPLENOMEGALY WITH FATTY LIVER
: RIGHT RENAL CALCULUS.**

ADVICE : STOOL FOR OPC.

Checked by :

DR. S.K. DAS
MBBS MD (RADIOLOG)
CONSULTANT RADIOLOGIST